

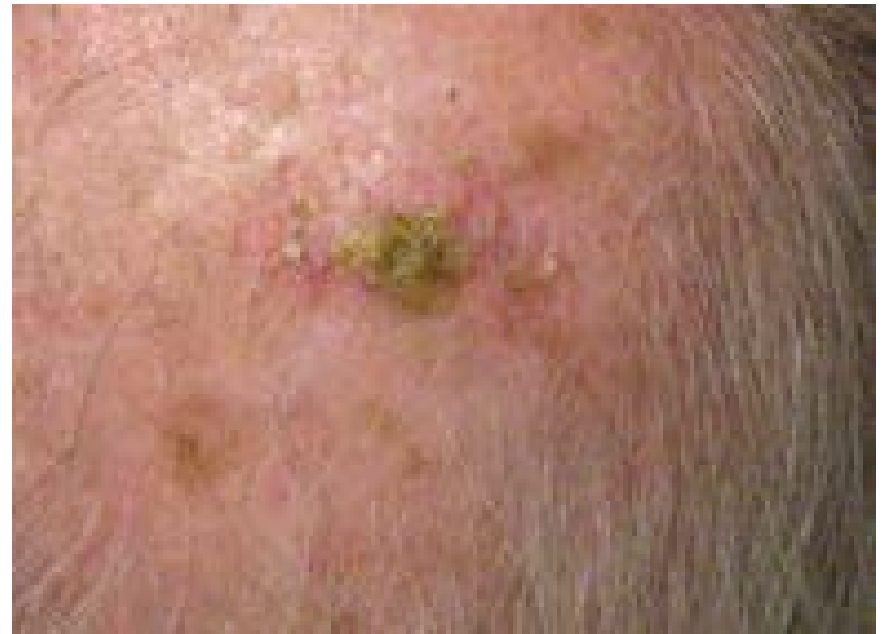Photo quiz 2

For residents beginning 2nd year family medicine
Christine Rivet

Photos from Dr James Walker and Dr Christine Rivet

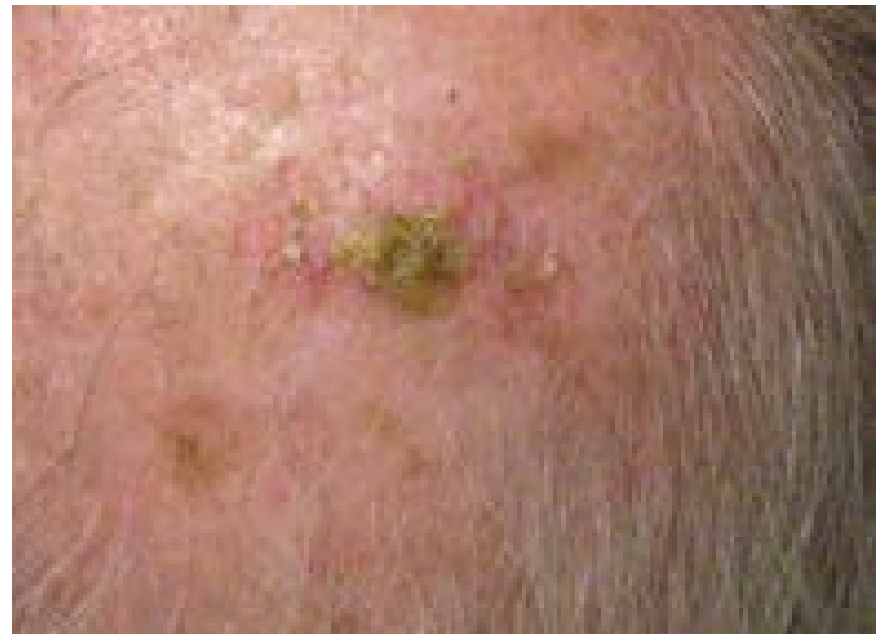Q-72 year old man with a bump on his bald scalp

- Possible diagnoses (choose all that apply)
- A-BCC
- B-thick actinic keratosis
- C-seborrheic keratosis
- D-SCC
- E-melanoma



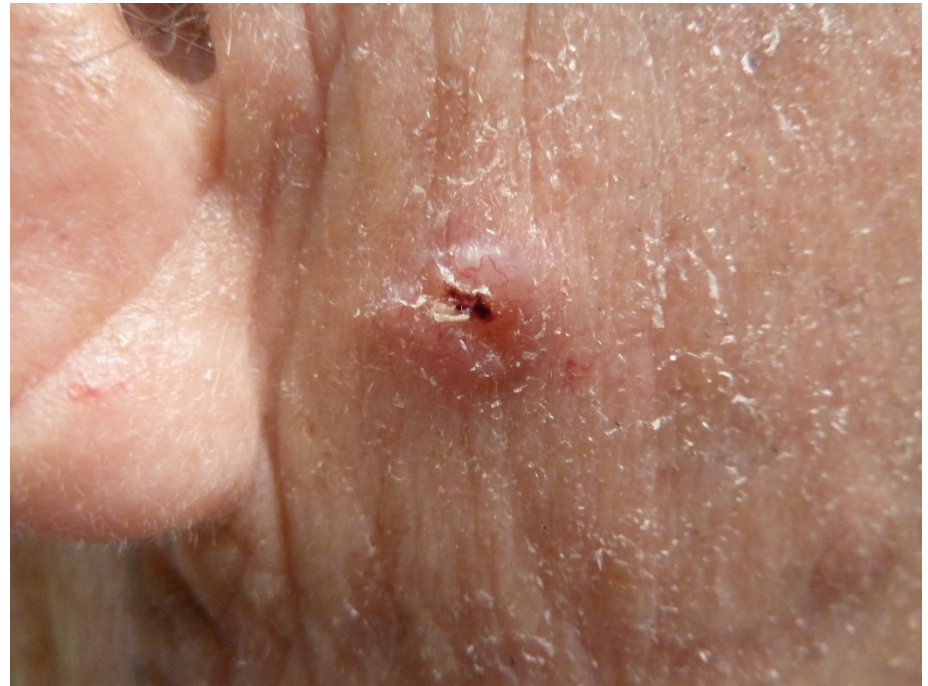A-72 year old man with a bump on his bald scalp

- Possible diagnoses
(choose all that apply)
- A-BCC
- **B-thick actinic keratosis**
- **C-seborrheic keratosis**
- **D-SCC**
- E-melanoma



Q-82 y o man with a bump in front of his ear

- He doesn't know how long he has had it. It only bleeds when he shaves over it.
- This is most likely(one answer):
- 1-seborrheic keratosis
- 2-actinic keratosis
- 3-basal cell carcinoma
- 4-squamous cell carcinoma
- 5-melanoma



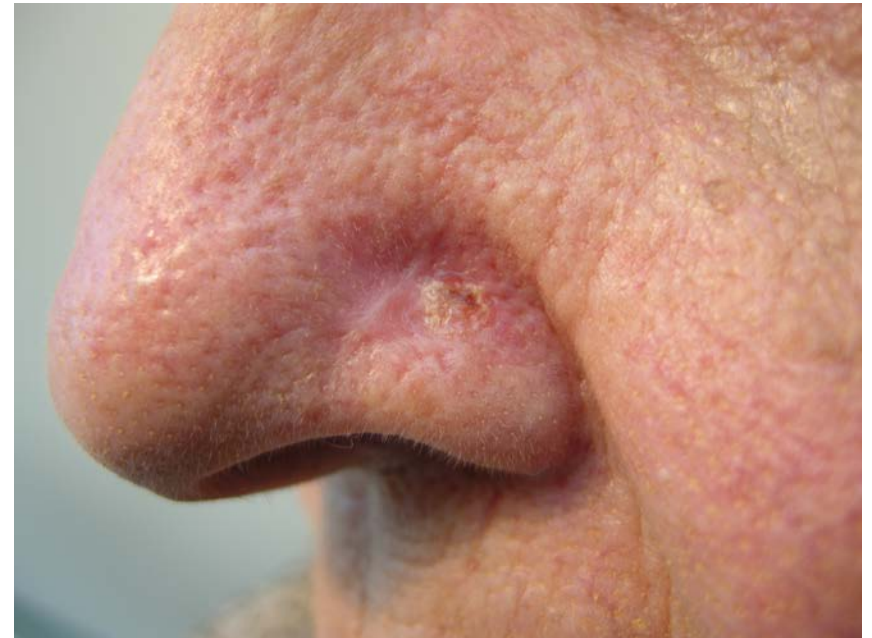A-82 y o man with a bump in front of his ear

- He doesn't know how long he has had it. It only bleeds when he shaves over it.
- This is most likely(one answer):
- 1-seborrheic keratosis
- 2-actinic keratosis
- **3-basal cell carcinoma**
- 4-squamous cell carcinoma
- 5-melanoma



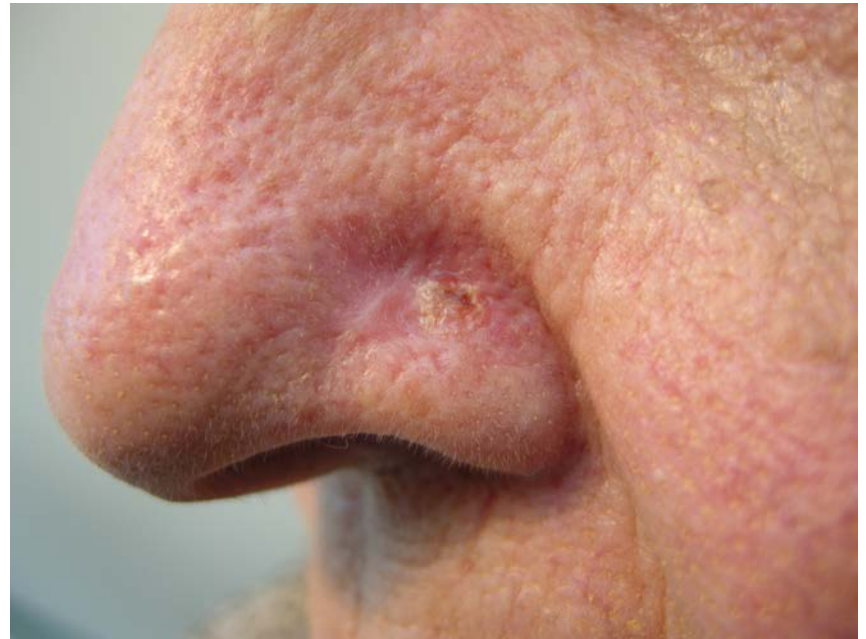Q-65 year old man with a persistent 'scab'(crust) of 6 wks duration in a scar from a previous basal cell carcinoma excision 3 years ago

- What is the most likely diagnosis?
- A- seborrheic keratosis
- B- actinic keratosis
- C-basal cell carcinoma
- D-squamous cell carcinoma
- E-melanoma



A-65 year old man with a persistent 'scab' (crust) of 6 wks duration in a scar from a previous basal cell carcinoma excision 3 years ago

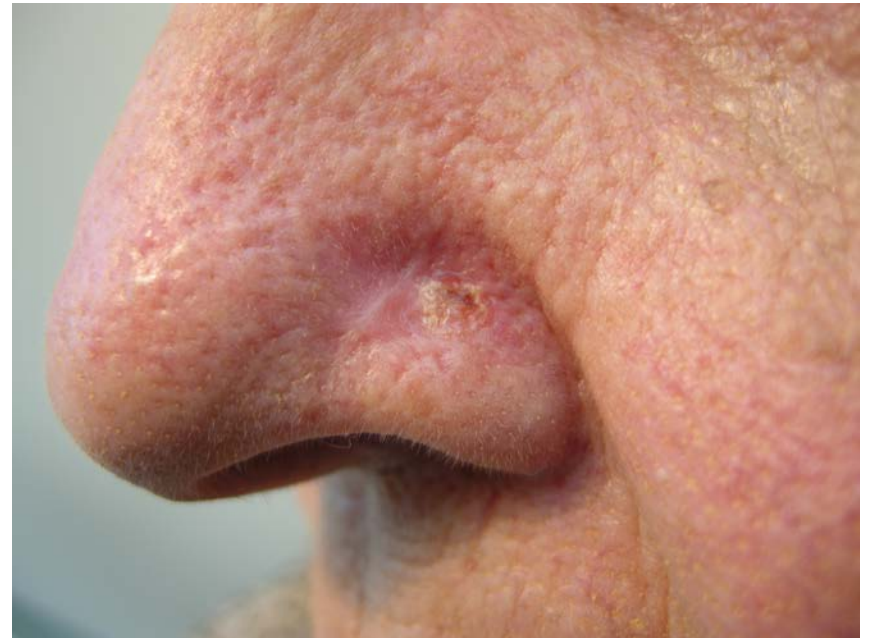- What is the most likely diagnosis?
- A- seborrheic keratosis
- B- actinic keratosis
- **C-basal cell carcinoma**
- D-squamous cell carcinoma
- E-melanoma



Q-What is the best definitive treatment for the patient in the previous slide?

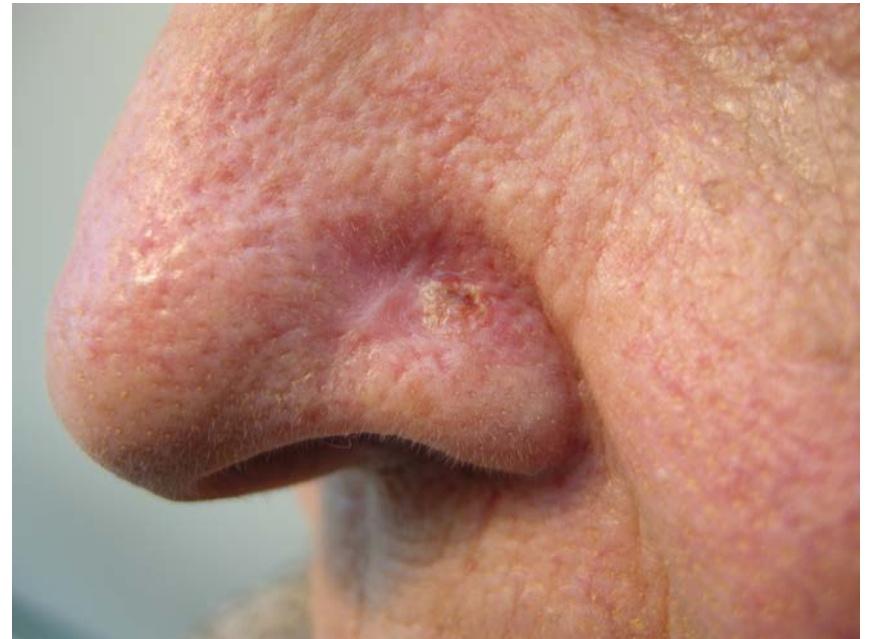(one answer)

- A-Observation
- B-Liquid nitrogen
- C-Shave excision
- D-Mohs surgery
- E-Elliptical excision



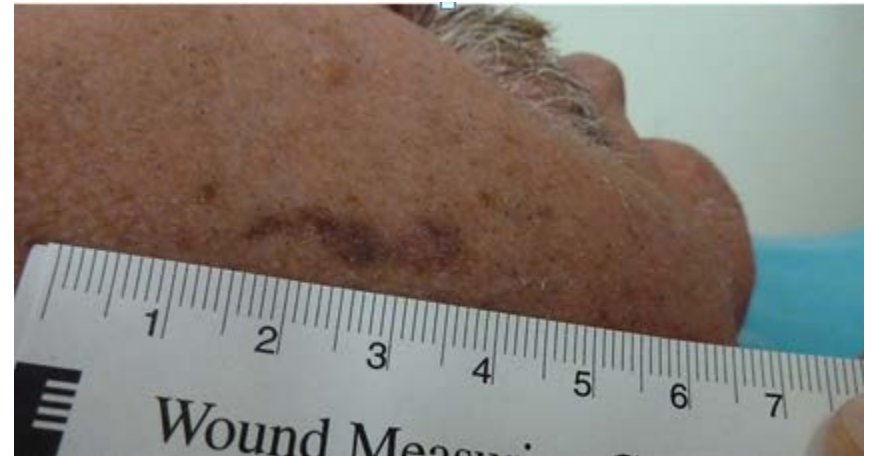A-What is the best treatment for the patient in the previous slide?
(one answer)

- Observation
- Liquid nitrogen
- Shave excision
- **Mohs surgery**
- Elliptical excision



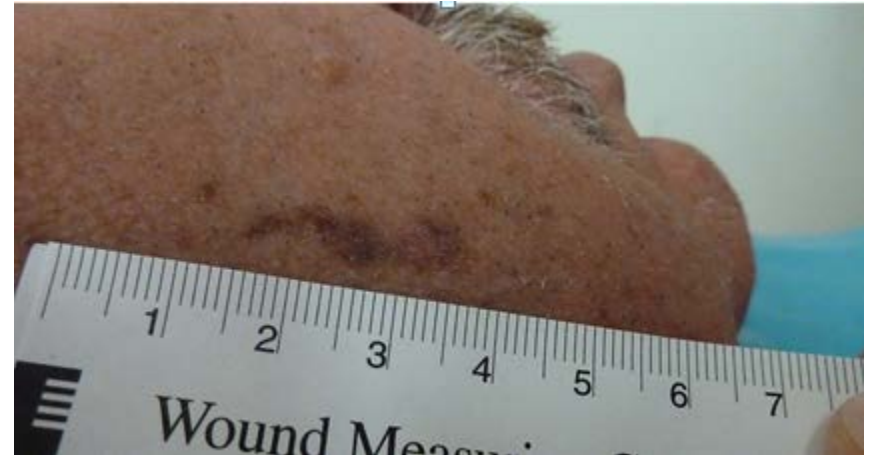Q 62 y o man with a longstanding mole on his R cheek

- He has had it for several years. He thinks it is slowly growing.
- What is the most likely diagnosis (one answer):
- 1-seborrheic keratosis
- 2-actinic keratosis
- 3-basal cell carcinoma
- 4-squamous cell carcinoma
- 5-melanoma



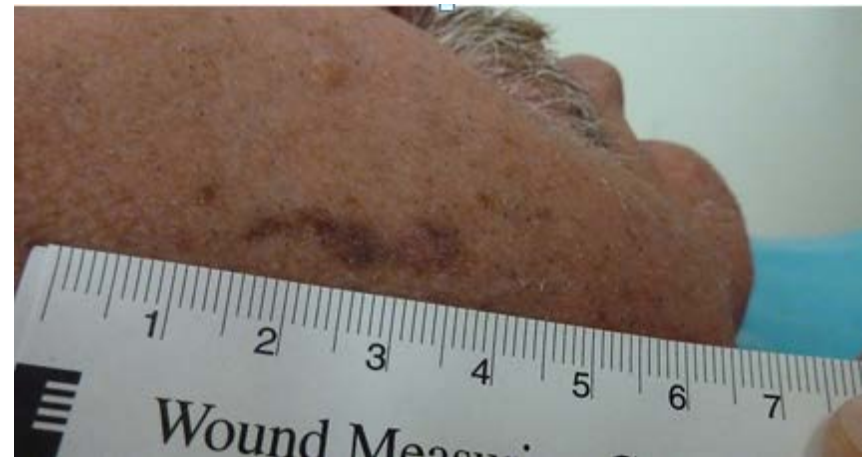A 62 y o man with a longstanding mole on his R cheek

- He has had it for several years. He thinks it is slowly growing.
- What is the most likely diagnosis (one answer):
- 1-seborrheic keratosis
- 2-actinic keratosis
- 3-basal cell carcinoma
- 4-squamous cell carcinoma
- **5-melanoma**



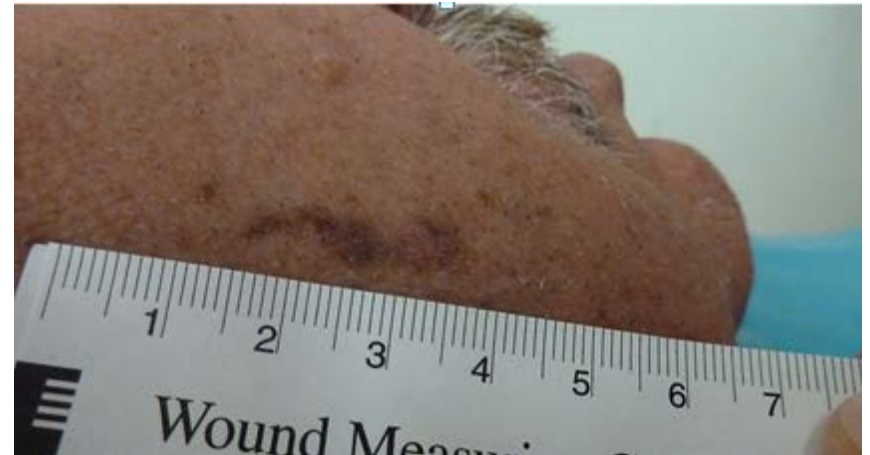Q 62 y o man with a longstanding mole on his R cheek

- What is your initial office management? (all that apply)
- A-observation for 3 months, then recheck.
- B-liquid nitrogen 3 applications then follow-up.
- C-shave excision and curettage.
- D-punch biopsies.
- E-urgent referral to dermatology.



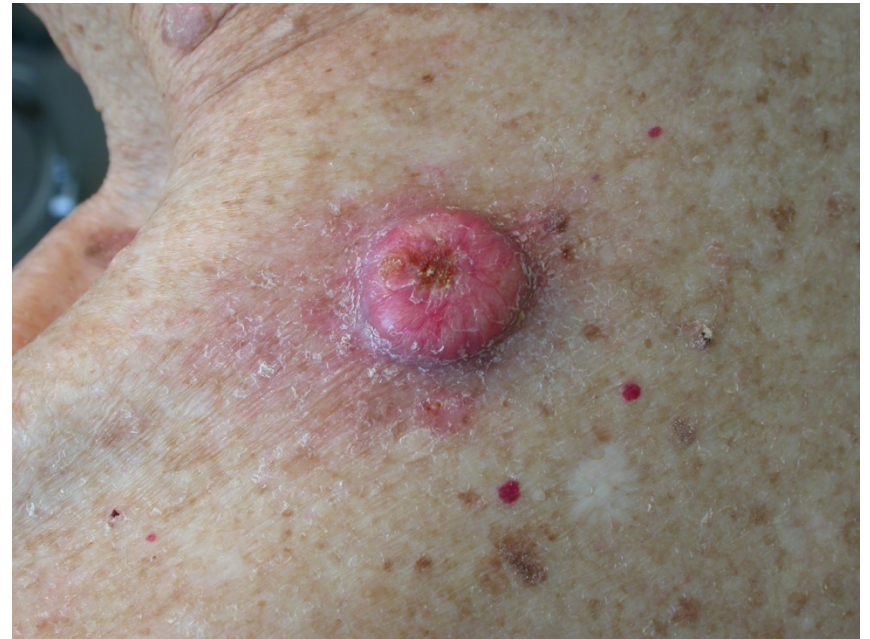A- 62 y o man with a longstanding mole on his R cheek

- What is your initial office management? (all that apply).
- A-observation for 3 months, then recheck.
- B-liquid nitrogen 3 applications, then follow-up.
- C-shave excision and curettage.
- **D-punch biopsies.**
- **E-urgent referral to dermatology.**



Q-A 68 y o man with a new lump on his upper back

- It has been present for 3 months and is growing rapidly.
- This is most likely(one answer):
- 1-seborrheic keratosis
- 2-actinic keratosis
- 3-basal cell carcinoma
- 4-squamous cell carcinoma
- 5-melanoma



A- A 68 y o man with a new lump on his upper back

- It has been present for 3 months and is growing.
- This is most likely(one answer):
- 1-seborrheic keratosis
- 2-actinic keratosis
- 3-basal cell carcinoma
- **4-squamous cell carcinoma**
- 5-melanoma



Q-A 68 y o man with a new lump on his upper back

- How do you treat this(all that apply)?
- A-observation for 3 mos
- B-liquid nitrogen and repeat in one month
- C-shave excision, curettage and desiccation
- D-elliptical excision
- E-wide excision with 1 cm borders



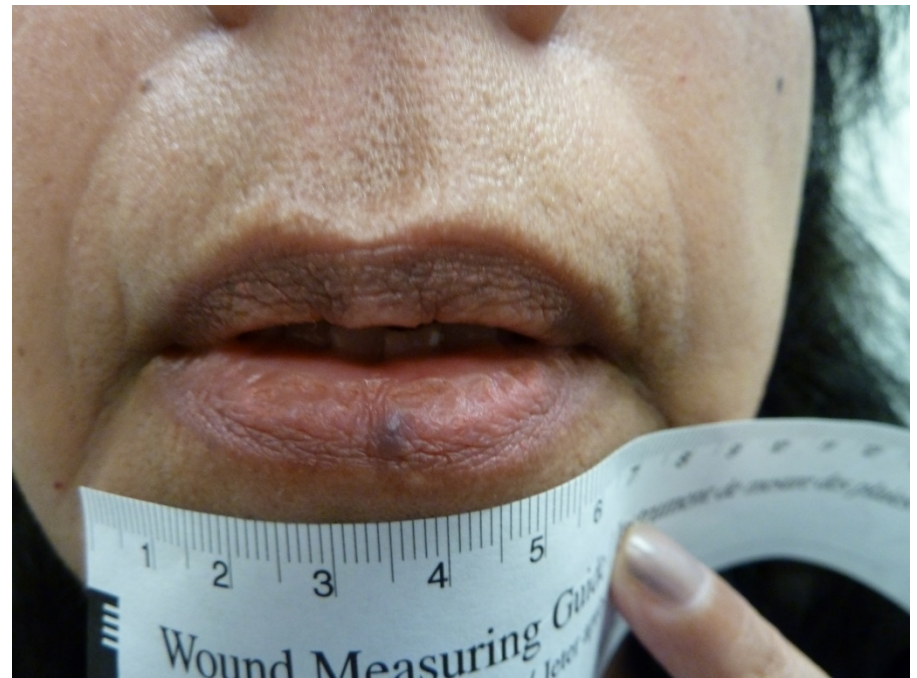A-A 68 y o man with a new lump on his upper back

- How do you treat this(all that apply)?
- A-observation for 3 mos
- B-liquid nitrogen and repeat in one month
- **C-shave excision, curettage and desiccation**
- **D-elliptical excision**
- E-wide excision with 1 cm borders



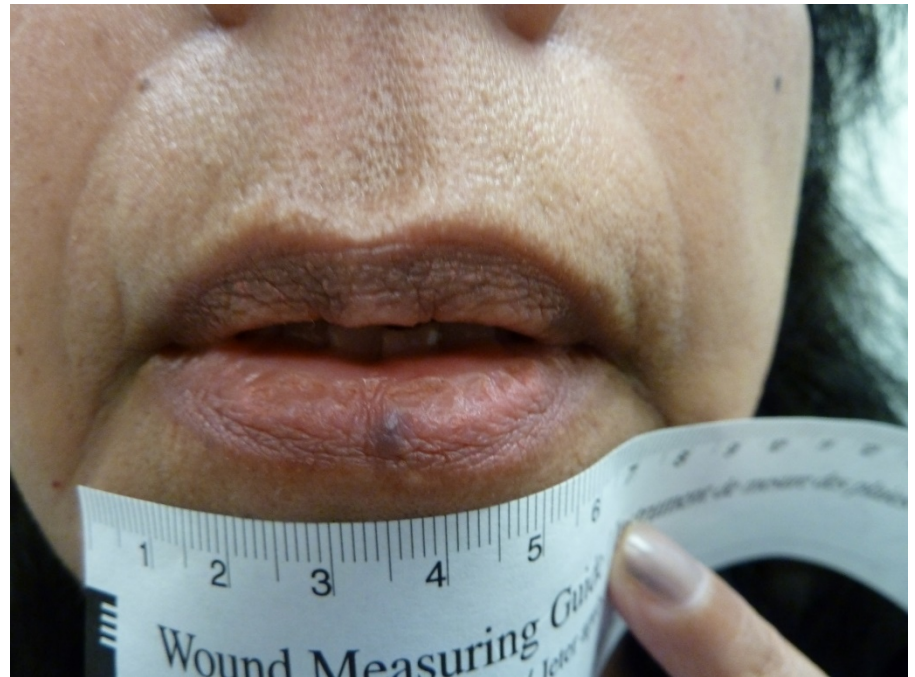Q-46 y o woman with a dark spot on her lower lip

- She says she has had it for 10 or 15 years and it has not changed.
- This is most likely(one correct):
- A-dermal nevus
- B-melanoma
- C-venous lake
- D-actinic cheilitis



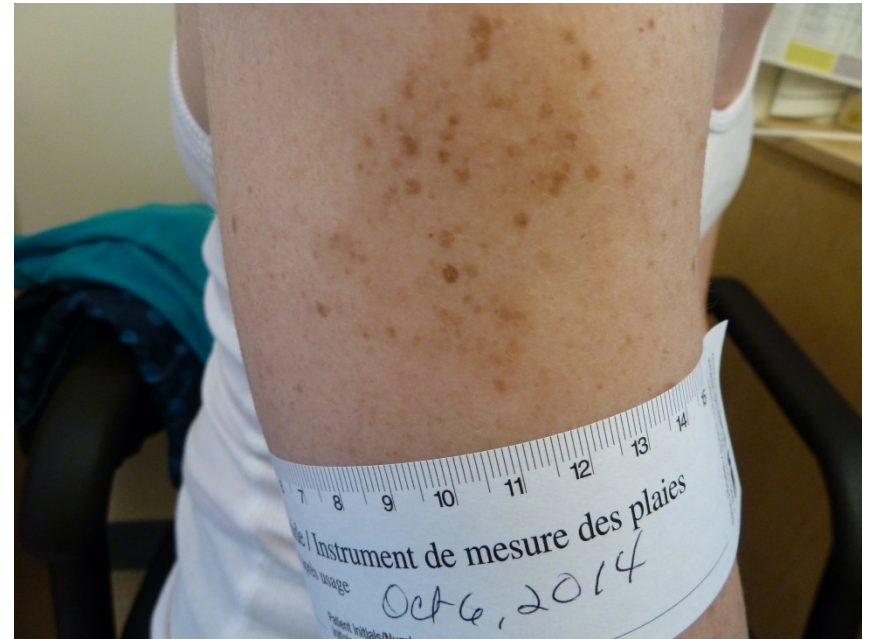A-46 y o woman with a dark spot on her lower lip

- She says she has had it for 10 or 15 years and it has not changed.
- This is most likely(one correct):
- A-dermal nevus
- B-melanoma
- **C-venous lake**
- D-actinic cheilitis



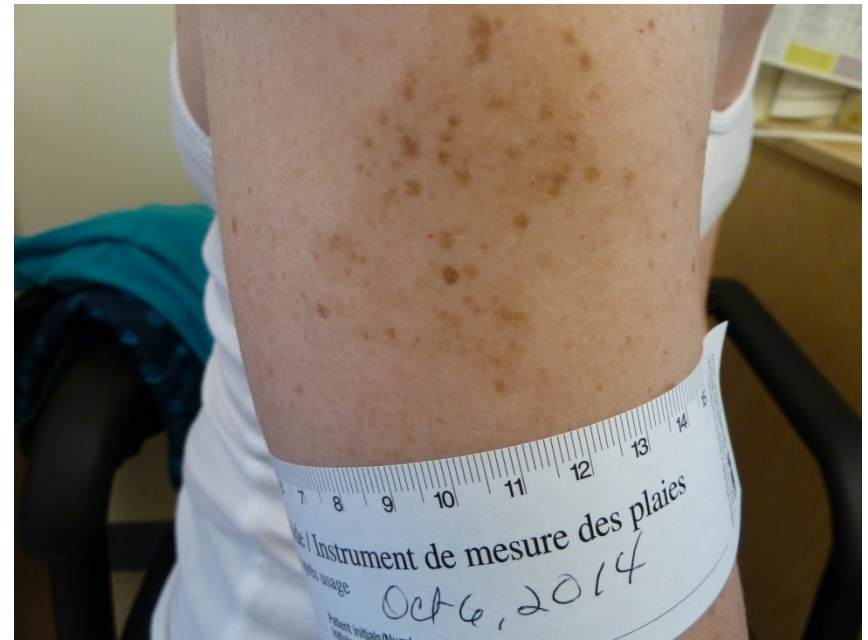Q-23 y o woman with a large brown patch on her arm;
it hasn't changed and has been there since she was a
child; she wants to know what it is?

- This is most likely:
- A-benign nevus
- B-actinic keratosis
- C-solar lentigo
- D-lentigo maligna



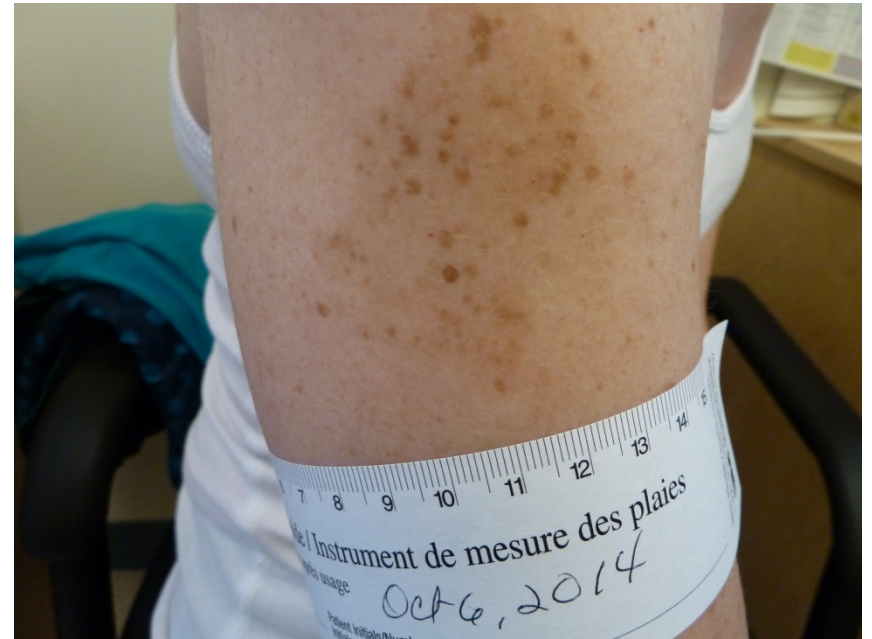A-23 y o woman with a large brown patch on her arm;
it hasn't changed and has been there since she was a
child; she wants to know what it is?

- This is most likely:
- **A-benign nevus**
- B-actinic keratosis
- C-solar lentigo
- D-lentigo maligna



Q-The best treatment for the 23 y o woman is(one best answer):

- A-observation
- B-liquid nitrogen
- C-small shave biopsy
- D-small punch biopsy



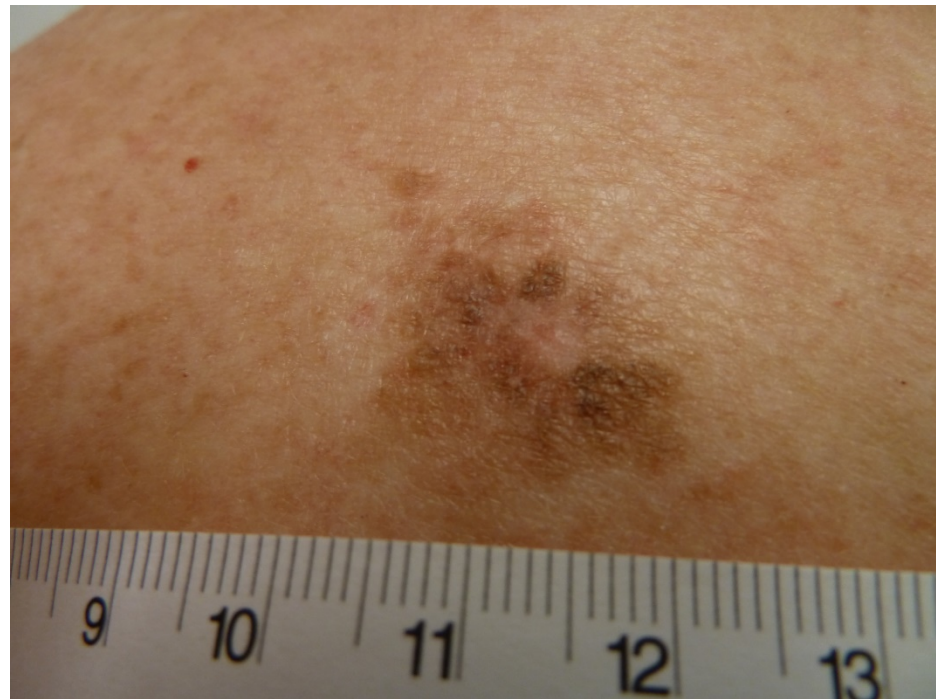
A-The best treatment for the 23 y o woman is(one best answer):

- **A-observation**
- B-liquid nitrogen
- C-small shave biopsy
- D-small punch biopsy



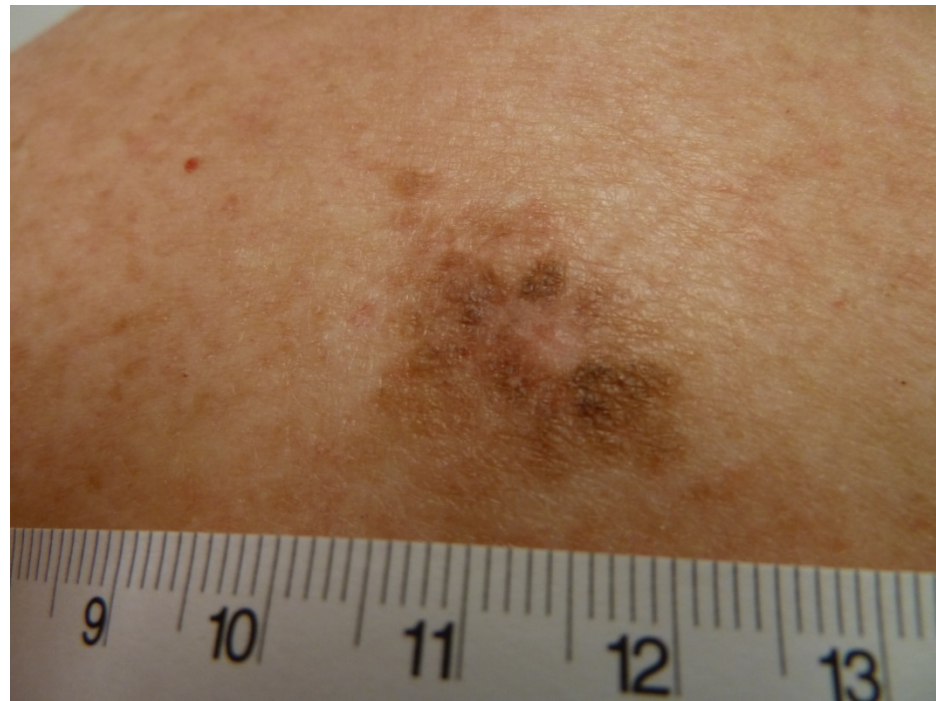
Q-Your patient's path report for the spot on her back, which was completely removed with 5 mm margins, says 'melanoma in situ.'

- What do you tell her about her 5 year prognosis?
- A-about 40% survival
- B-about 60% survival
- C-about 80% survival
- D-about 100% survival



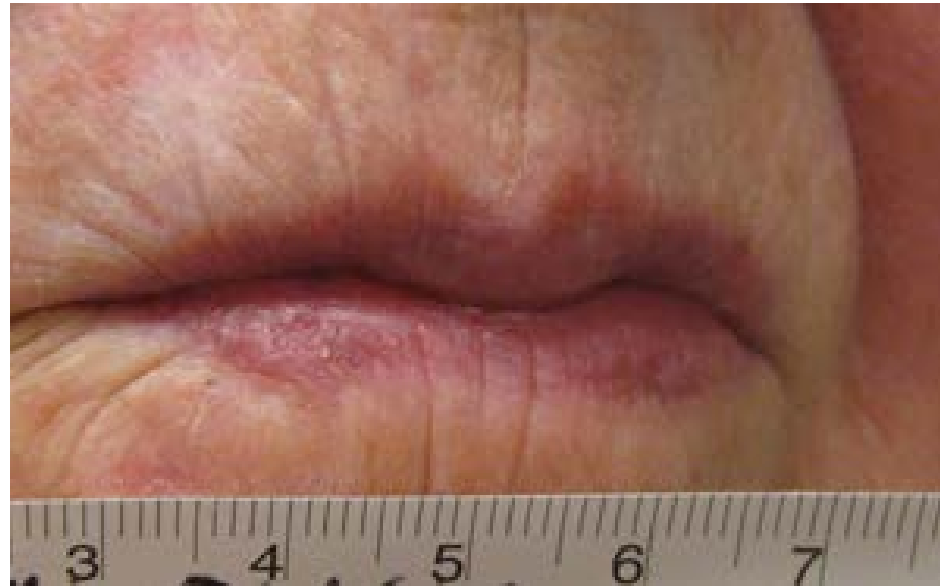A-Your patient's path report for the spot on her back, which has been completely removed with 5 mm margins, says 'melanoma in situ.'

- What do you tell her about her 5 year prognosis?
- A-about 40% survival
- B-about 60% survival
- C-about 80% survival
- **D-about 100% survival**



Q-A 71 year old woman has noticed some rough areas on her lower lip which have been there for months and have not improved with topical steroids.

- What is the most likely diagnosis?(one answer)
- A-solar lentigo
- B-actinic cheilitis
- C-irritant cheilitis
- D-contact dermatitis
- E-seborrheic dermatitis



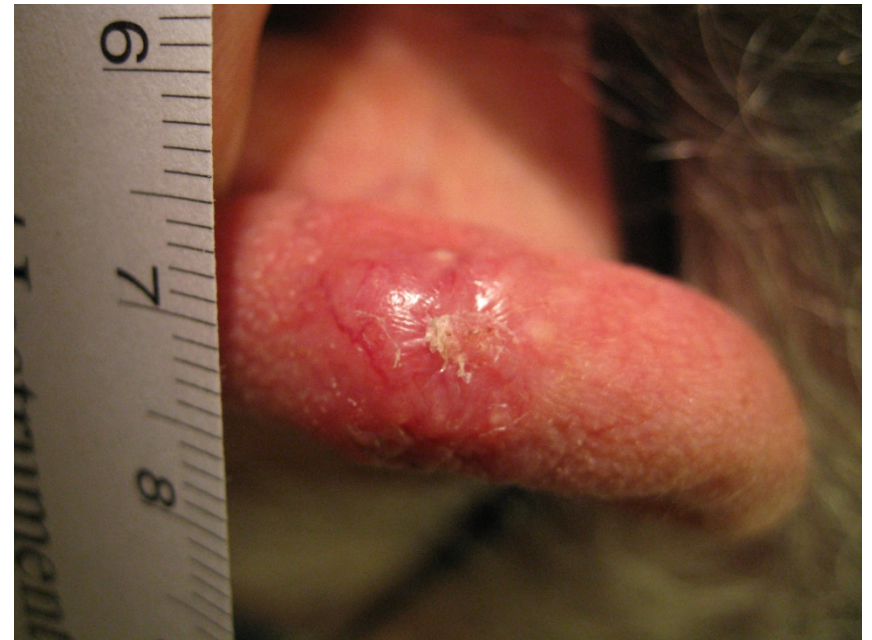A-A 71 year old woman has noticed some rough areas on her lower lip which have been there for months and have not improved with topical steroids.

- What is the most likely diagnosis?(one answer)
- A-solar lentigo
- **B-actinic cheilitis**
- C-irritant cheilitis
- D-contact dermatitis
- E-seborrheic dermatitis



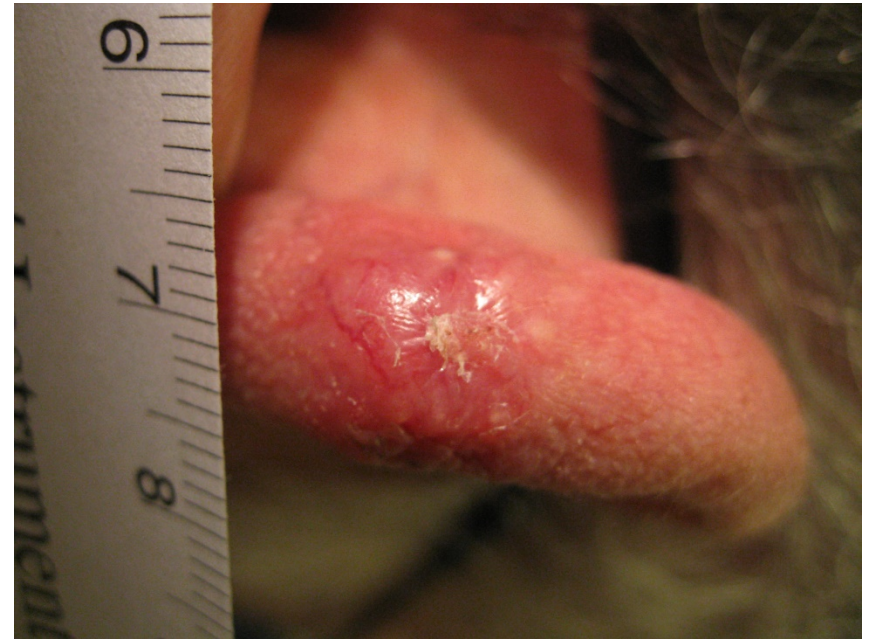Q-A 52 y o man with a lesion on his ear. He thinks it has been there for about 6 months and appears to heal at times but has never gone away completely.

- The most likely diagnosis is(one answer):
- 1-seborrheic keratosis
- 2-actinic keratosis
- 3-basal cell carcinoma
- 4-squamous cell carcinoma
- 5-melanoma



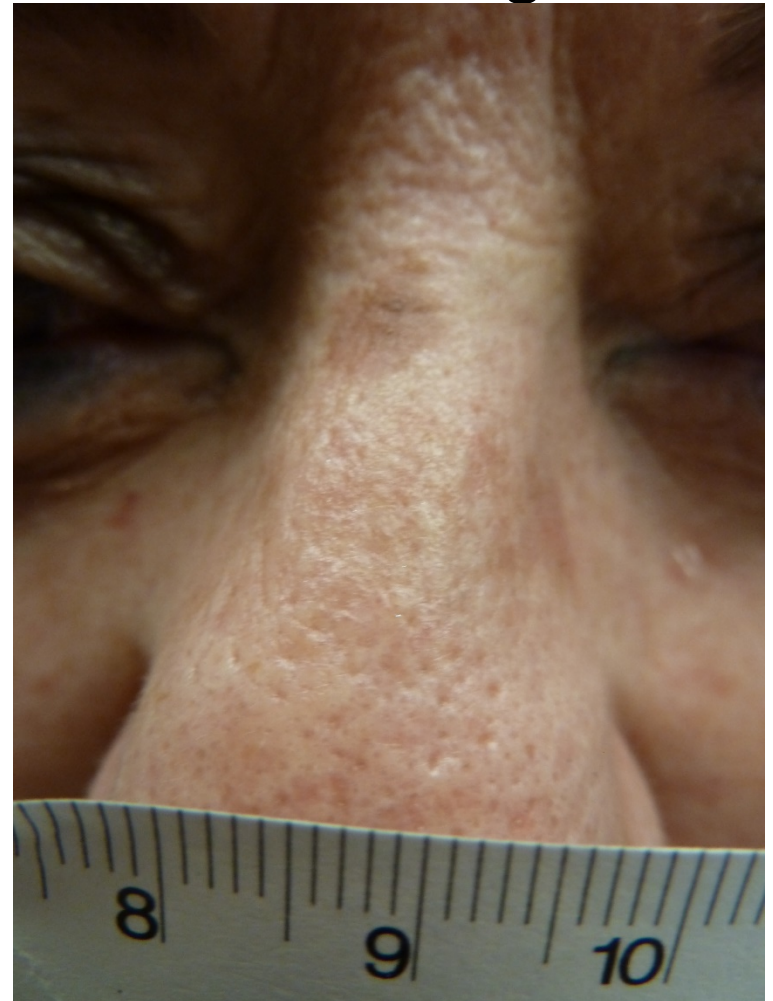
A-A 52 y o man with a lesion on his ear. He thinks it has been there for about 6 months and appears to heal at times but has never gone away completely.

- The most likely diagnosis is(one answer):
- 1-seborrheic keratosis
- 2-actinic keratosis
- **3-basal cell carcinoma**
- 4-squamous cell carcinoma
- 5-melanoma



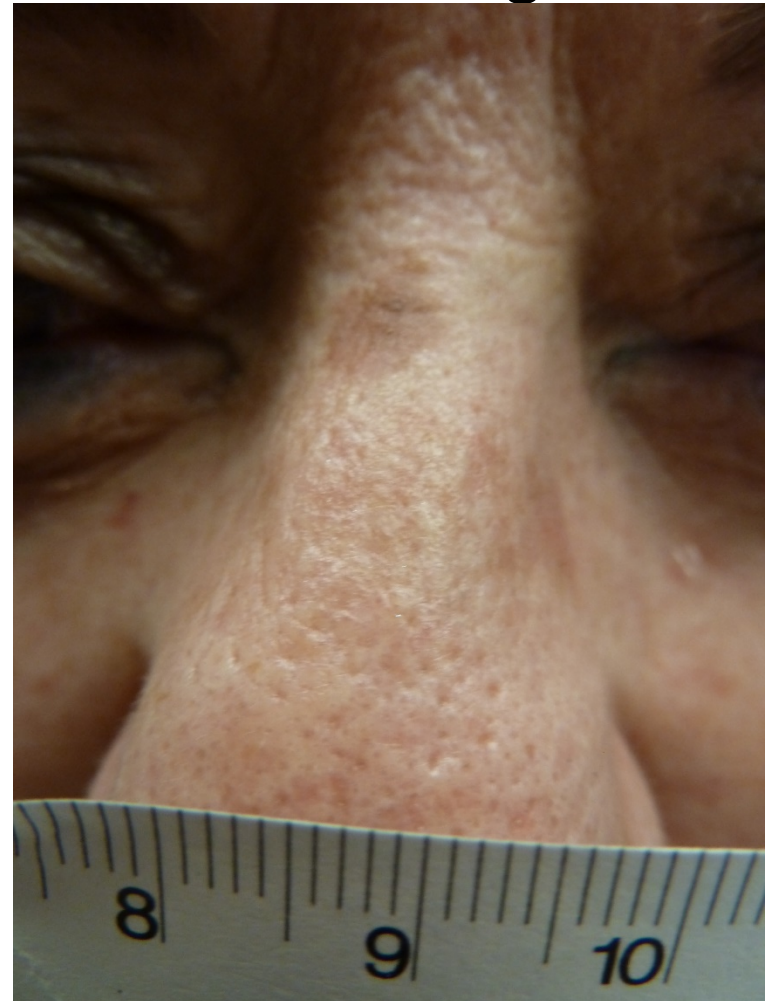
Q-A 58 y o woman wants to know what this large freckle is on the proximal bridge of her nose. It has been present a few years and has not changed.

- This spot is most likely (one correct answer):
- A-actinic keratosis
- B-solar lentigo
- C-pigmented basal cell carcinoma
- D-squamous cell carcinoma
- E-melanoma



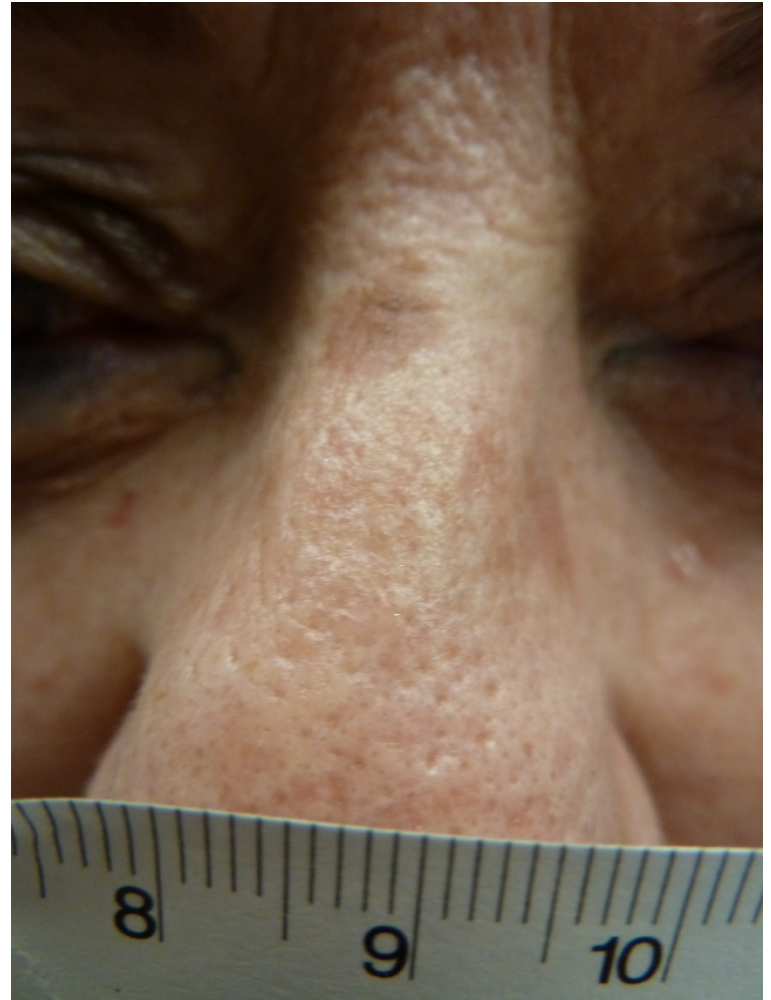
A 58 y o woman wants to know what this large freckle is on the proximal bridge of her nose. It has been present a few years and has not changed.

- This spot is most likely (one correct answer):
- A-actinic keratosis
- **B-solar lentigo**
- C-pigmented basal cell carcinoma
- D-squamous cell carcinoma
- E-melanoma



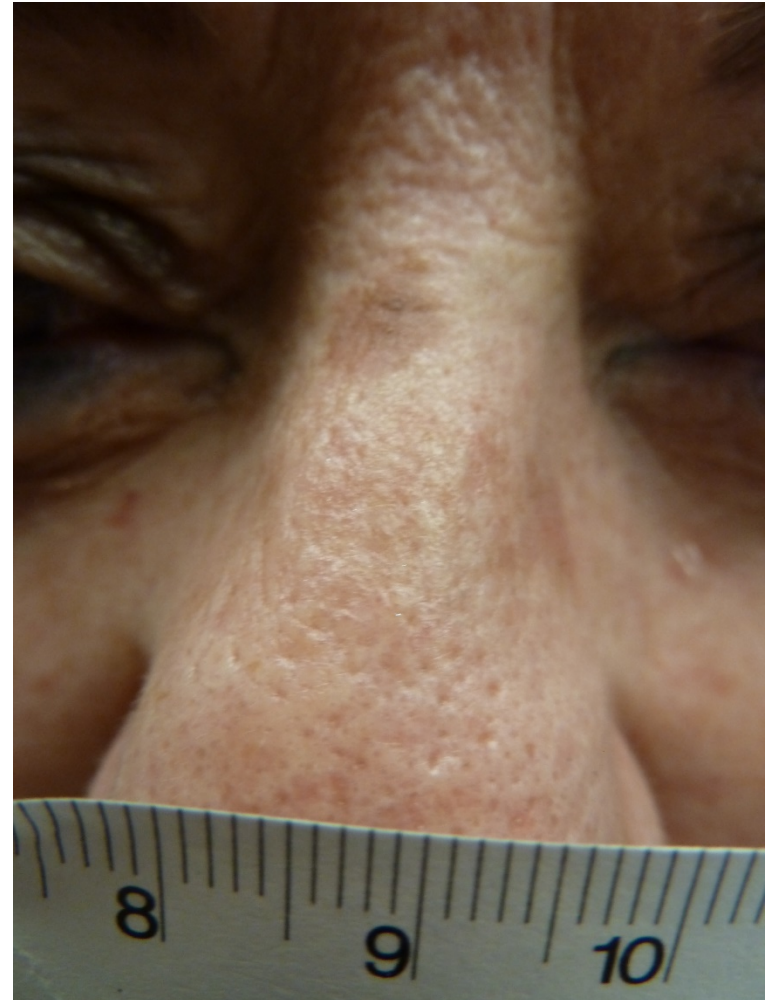Q-A 58 y o woman from the previous question wants to know what she can do about this lesion on her proximal nose?.

- What are recommended managements? (all that apply).
- A-observation
- B-liquid nitrogen
- C-conservative elliptical excision
- D-wide elliptical excision
- E-urgent consult to dermatologist



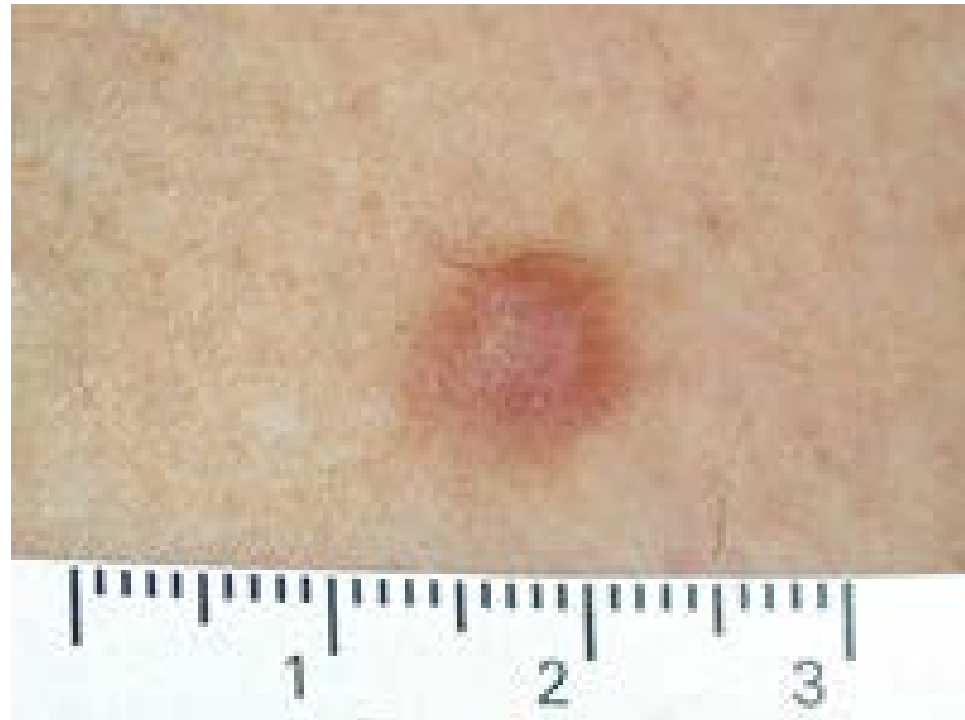A-A 58 y o woman from the previous question wants to know what she can do about this lesion on her proximal nose?.

- What are recommended managements? (all that apply).
- **A-observation**
- **B-liquid nitrogen**
- C-conservative elliptical excision
- D-wide elliptical excision
- E-urgent consult to dermatologist



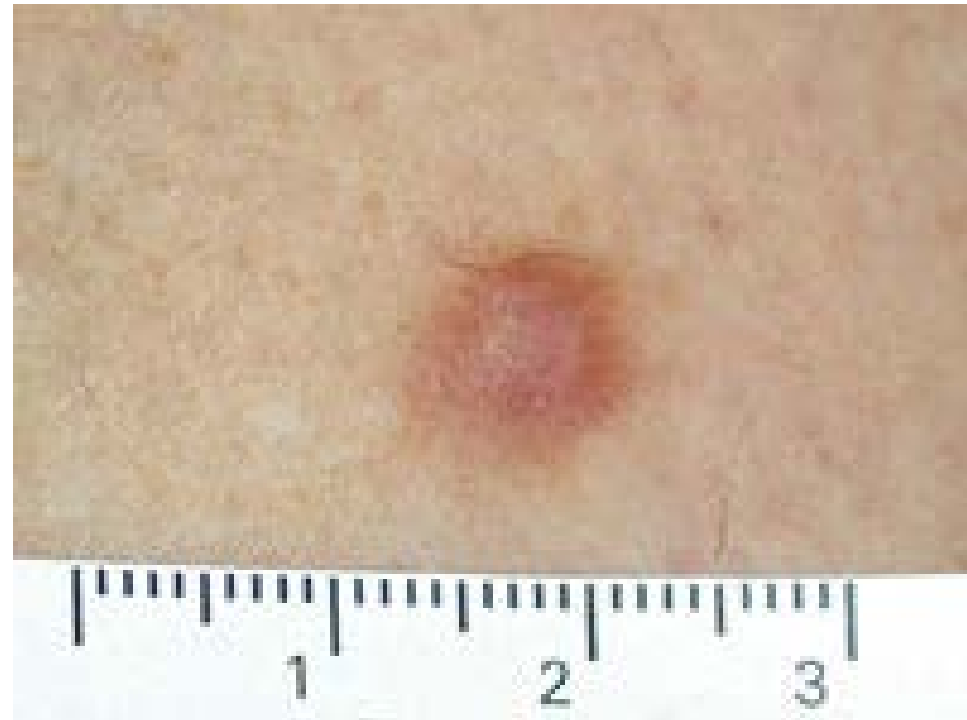Q 47 y old woman with a firm lump on her R leg. She doesn't think it has changed and she'd like to know what this is?

- This is most likely (one correct):
- 1-basal cell carcinoma
- 2-squamous cell carcinoma
- 3-solar lentigo
- 4-dermatofibroma
- 5-melanoma



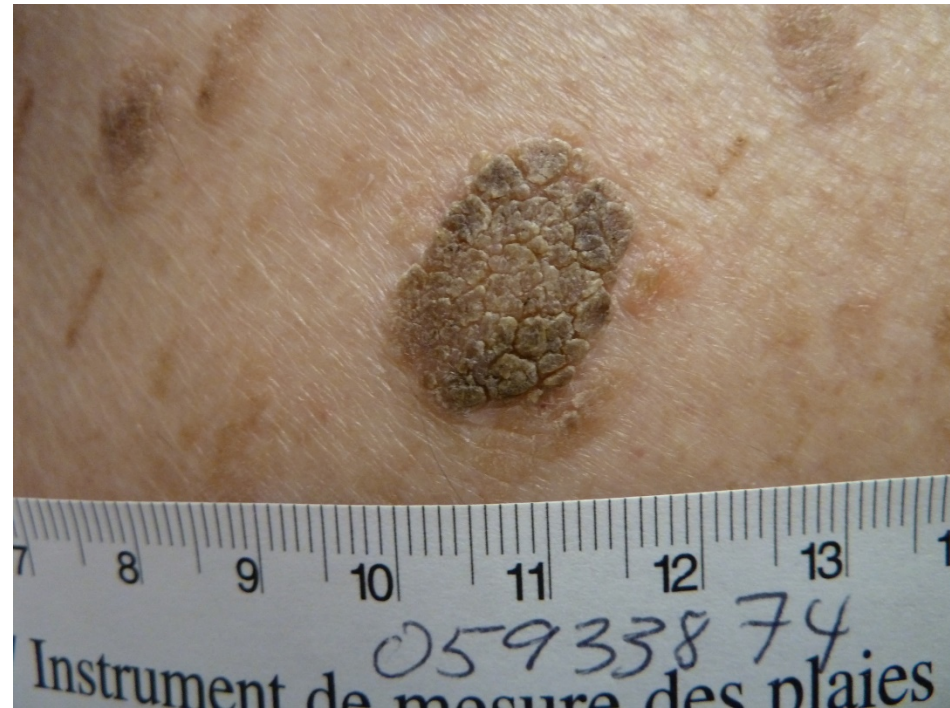A- 47 y old woman with a firm lump on her R leg. She doesn't think it has changed and she'd like to know what this is?

- This is most likely (one correct):
- 1-basal cell carcinoma
- 2-squamous cell carcinoma
- 3-solar lentigo
- **4-dermatofibroma**
- 5-melanoma



Q-A 67 y o man's wife says she thinks this growth on his back is ugly. She only noticed it recently and doesn't know if it has changed.

- What is the most likely diagnosis(choose only one answer):
- 1-actinic keratosis
- 2-seborrheic keratosis
- 3-basal cell carcinoma
- 4-squamous cell carcinoma
- 5-melanoma



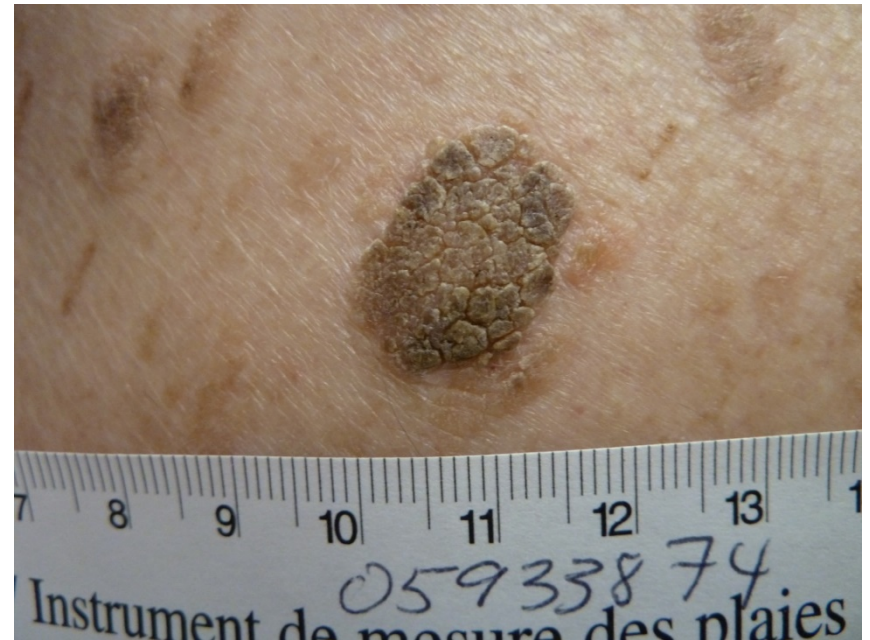A 67 y o man's wife says she thinks this growth on his back is ugly. She only noticed it recently and doesn't know if it has changed.

- What is the most likely diagnosis(choose only one answer):
- 1-actinic keratosis
- **2-seborrheic keratosis**
- 3-basal cell carcinoma
- 4-squamous cell carcinoma
- 5-melanoma



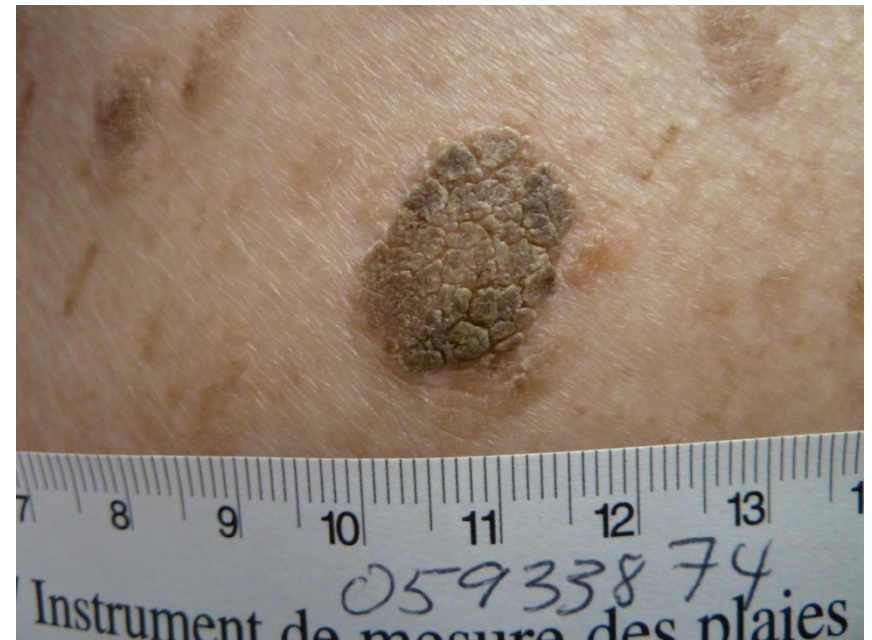
Q-A 67 y o man's wife says she thinks this growth on his back is ugly. She only noticed it recently and doesn't know if it has changed

- What are recommended treatments? Answer all that apply.
- A-observation
- B-liquid nitrogen
- C-shave excision
- D-elliptical excision
- E-wide excision



A-A 67 y o man's wife says she thinks this growth on his back is ugly. She only noticed it recently and doesn't know if it has changed

- What are recommended treatments? Answer all that apply.
- **A-observation**
- **B-liquid nitrogen**
- **C-shave excision**
- D-elliptical excision
- E-wide excision



The end